

# Hair Transplantation in Patients With Inadequate Head Donor Supply Using Nonhead Hair

## Report of 3 Cases

Sanusi Umar, MD\*†

**Abstract:** Follicular unit extraction is becoming an increasingly popular technique for hair transplantation as it obviates the linear scarring associated with strip harvesting, and can provide highly presentable results. Using this technique, a few reports have described the small scale use of nonhead hair for head hair transplantation in men with inadequate head hair donor supply. In this report, 3 patients who were severely bald had hairs transplanted from the chest, abdomen, legs, shoulders, or beard, as well as the head to achieve full coverage and excellent hairlines. Of the 3 cases, 2 had undergone previously unsuccessful hair transplant surgeries. Approximately 80% to 85% of the transplanted grafts survived. Although hair length and quality, surgery time, and the requirement for improved surgical skills remain challenges when using this technique, the sufficiently good outcomes from these selected candidates suggest that this technique may offer the possibility of restoring even severely bald states to normality in patients who would otherwise not be candidates for traditional hair transplantation surgery.

**Key Words:** hair transplantation, follicular unit extraction, nonhead hair transplantation

(*Ann Plast Surg* 2011;XX: 000–000)

Conventional hair transplants largely consist of the harvesting of hair from the back and sides of the head by a strip harvesting method that entails removal of a strip of flesh from which the hair is derived for grafting to bald areas.<sup>1</sup> The resulting linear wound is closed to create a linear scar, which can widen and be unsuitable for patients wishing to keep their hair short. A newer alternative for some patients, termed the follicular unit extraction (FUE) procedure, was described by Rassman et al<sup>2</sup> based on original work carried out by Inaba,<sup>3</sup> who first described a similar technique in his 1996 textbook. FUE involves harvesting of the hair follicle grafts by using punch devices to cut a circular path around individual follicular units from the epidermis into the dermis.<sup>4</sup>

While harvesting of hair from the head has only become the norm for FUE for implantation to bald areas of the scalp (Rassman et al<sup>2</sup>), an earlier report by Hirai et al<sup>5</sup> had described the use of modified 18-gauge hypodermic needles to harvest small amounts of beard hair by cutting around single follicles to the level of the subdermis. The hair follicles were then pulled out and used to successfully restore the eyebrows of 3 patients. In both instances, it was noted that when a 1-mm punch was used,

the donor area was devoid of cosmetically significant scarring. Woods and Campbell<sup>6</sup> extended the observation that body hair can be used with the FUE technique in suitable patients and reported a case from whom 1500 chest hairs were harvested and grafted to the scalp of a patient whose head donor supply had been depleted from prior poorly executed hair transplant surgeries. They reported extended growth of chest hair from 4 cm in the original chest location to 15 cm in the new scalp location.

Regardless of the type of surgery performed—FUE or strip harvesting method—the conventional approach to hair transplantation has understandably focused on the use of only head-derived hair as the donor source. Using conventional methods, the average safe donor area contains about 12,500 movable hairs<sup>7</sup> and because head grafts consist mostly of 2 to 3 hairs per follicle, this would translate to not more than 6000 follicles. However, this number would not adequately serve the needs of a severely bald individual ranking a 6 on the Norwood baldness scale, who has likely to have lost over 50,000 hairs (approximately 25,000 follicles). Consequently, conventional hair transplant providers have thus either considered such candidates inoperable or chosen to prioritize areas of coverage with the most common approach being to graft the front and top at the expense of the crown, which is left bald. The advent of FUE techniques allows for the extraction of hair follicles with less cosmetically significant scarring and has made for the possibility of using non-head hair in hair transplantation,<sup>5,6</sup> thus increasing the overall hair donor pool.

To date, there have been few reports in the literature on the use of nonhead hair as a donor source, and the reports that have been published focused on the small-scale use of non-head hair for minor restorations. The present report introduces the applications of large numbers (>8000 grafts) of nonhead hair (mainly body and beard sources) in hair transplantation using the FUE approach. All cases presented suffered hair loss that could not be met with the available head donor supply.

## MATERIALS AND METHODS

All patients were hirsute with indications for use of nonhead hair for hair transplantation. For body hair extractions, the body donor areas were pretreated with 5% minoxidil once or twice daily for a variable period of 6 weeks to 6 months before surgery, and anagen hair was specifically targeted by preshaving the areas 7 to 10 days before surgery.

The procedure was performed under local anesthesia by subcutaneous injections of epinephrine (1:100,000) and 1% lidocaine/0.25% marcaine in a 5:1 ratio for recipient areas, and a further dilution (5:1) with normal saline for donor areas. No attempt was made to tumesce the donor areas. Hypodermic needles (19- and 20-gauge) were modified at the tip to form a customized punch-like instrument that was mounted on a rotary tool. The rotating customized sharp needle tip was used to cut around individual hair follicles to a depth exceeding the bulge area. Each freed hair follicle was pulled out effortlessly with occasional aid of blunt needle tip dissection. Wounds created by the customized needle tip widen with

Received October 15, 2010, and accepted for publication, after revision, December 2, 2010.

From the \*Division of Dermatology, Department of Medicine, University of California, Los Angeles, CA; and †FineTouch Dermatology Inc., Redondo Beach, CA.

Reprints: Sanusi Umar, MD, FineTouch Dermatology Inc., 819 North Harbor Dr., Suite 400, Redondo Beach, CA 90277. E-mail: drumar@dermhairclinic.com.

Copyright © 2011 by Lippincott Williams & Wilkins

ISSN: 0148-7043/11/0000-0001

DOI: 10.1097/SAP.0b013e318209a61a

depth, hence minimizing injury to follicles and enhancing wound closure. For recipient grafting, slits were created using blades that were custom sized to the size of the extracted grafts. Time to complete surgery was 8 to 9 hours for 1500 to 1800 grafts, which was the usual number transplanted for each session, with 1 session per day. Patients required several sessions, which meant several consecutive days in surgery to achieve a large number of graft transfers.

### Donor Healing

Starting 2 weeks after surgery and at intervals of 4 weeks, the beard area of patients 1 and 3 received 4 laser treatments using either a fractionated erbium laser (Fraxel laser; Solta Medical, Hayward, CA) if the extraction site was noted to be depressed below skin level, or a 595-nm pulse dye laser with a V-beam (Perfecta; Candela, Irvine, CA) if redness was the dominant symptom.

### Test Patient

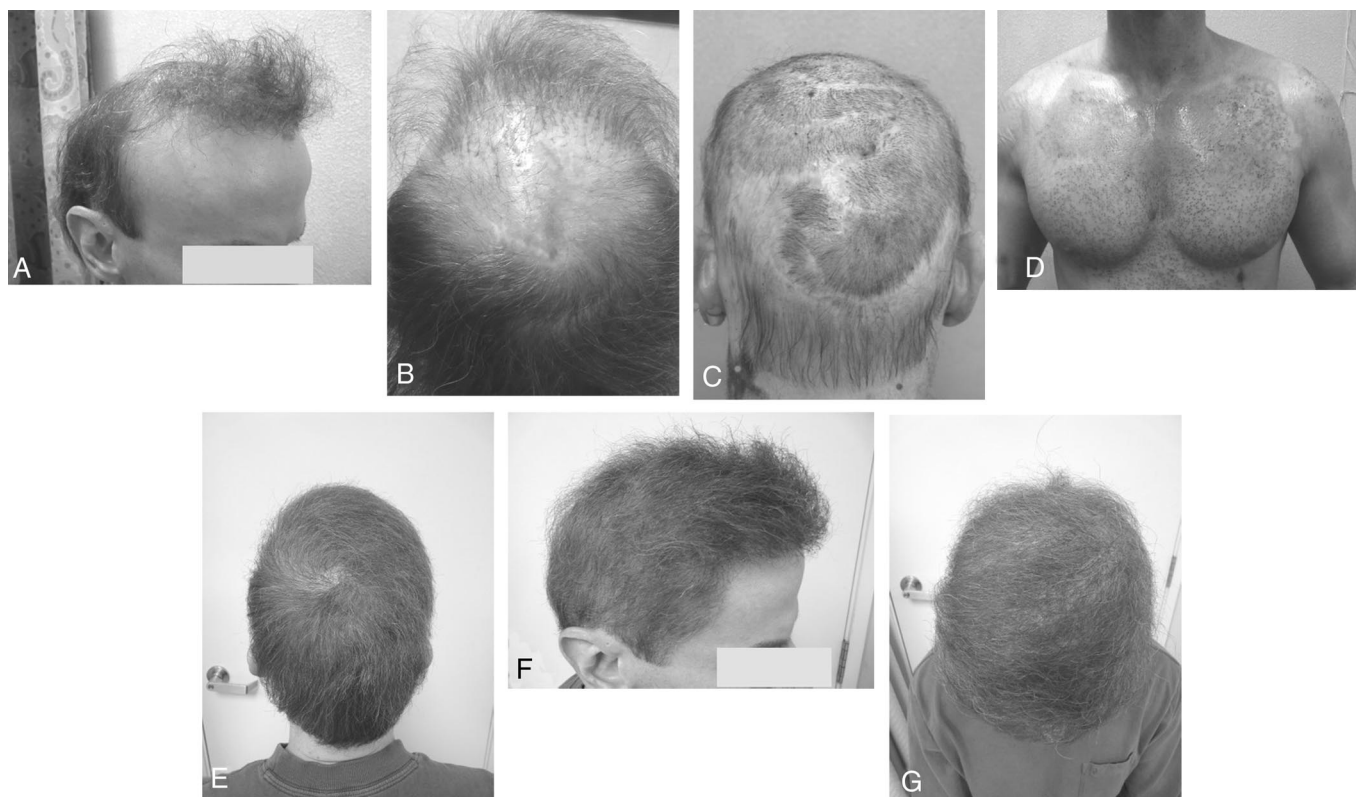
A 56-year-old white male had a slick bald crown and thinning that involved an area corresponding to a 3V on the Norwood-Hamilton scale of hair loss. He had no history of previous restoration surgeries. To determine whether the patient might be a candidate for nonhead hair transplantation and to evaluate the length of growth of nonhead hair from its original to transplanted location, the following procedures were performed: (1) in several 1 to 2.5 cm<sup>2</sup> patches of

the bald crown, several chest hair grafts were implanted; (2) in another area, several beard hair grafts were implanted; and (3) in another area, several head-derived hair grafts were implanted. The patient was instructed not to cut the test hairs until final examination 10 months postoperatively.

Both transplanted head and beard hair grew to an average length of 8.5 cm at 10 months. Untrimmed chest hair in the patient grew to an average length of 4 cm in its native chest location. After 10 months of growth in the new scalp location, chest hair grew to an average length of 4.5 cm.

### Patient 1

A 36-year-old white male had undergone several scalp reductions and follicular unit strip surgeries, resulting in a severe slot deformity of the crown, continuing baldness, plug-like transplants, and a hairline associated with ridging and pitting (Figs. 1A, B). He was severely bald with several cicatricial alopecia plaques in the head donor area and crown, and his head donor area was severely depleted (Fig. 1C). The patient had his slot deformity addressed with a tissue expansion and flap surgery prior to the current hair transplantation. Hair transplantation was carried out using about 12,000 chest (Fig. 1D), abdomen, and shoulder hair grafts, 9000 beard grafts, and 1000 head hair grafts to cover his bald areas and scars.



**FIGURE 1.** Case 1: A, Right oblique view: Loss of right parietal hair and temple secondary to patterned baldness and distortion of anatomy by the pulling forces of several scalp reductions. Thick plug-like transplants producing a scant forelock effect. B, Crown view: empty distorted crown occupied by a stretched scar of scalp reduction. Visible plug-like transplants in the frontal scalp. C, Back view (shaved): cicatricial (scarring) alopecia from multiple scalp surgeries. D, Chest area soon after extraction of chest grafts. E, Back view (1 year after repair with beard and body hair): Scars in the back are obscured with complete crown restoration and creation of a natural whorl. F, Right lateral view (1 year after repair with beard and body hair): Right parietal half and temples have been restored. Hairline and frontal scalp rehabilitated. G, Top view (1 year after repair with beard and body hair): Crown, midscalp, and front have been restored.

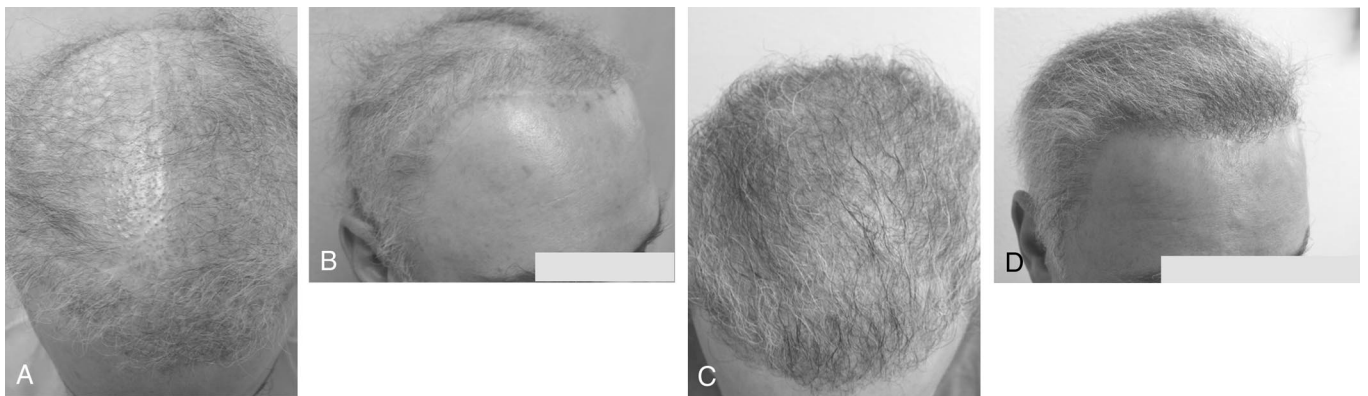Several thick plugs were removed to complete the repair. The procedure was completed in 3 major sessions at 6 monthly intervals.

Approximately 6 months after the last surgery the patient had attained total coverage with a nonreceding hairline with coverage of all scars (Figs. 1E–G). It was estimated that 85% of the grafts survived.

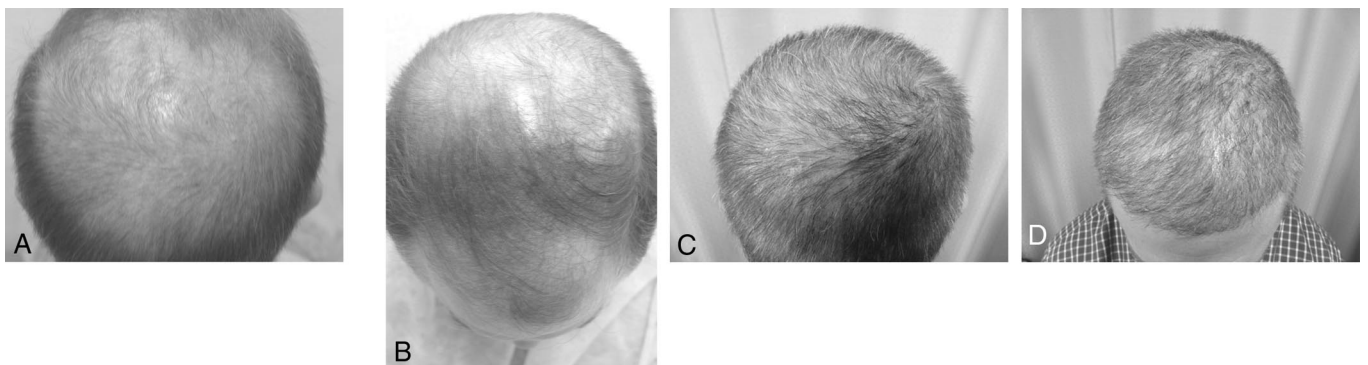
### Patient 2

A 54-year-old white male had undergone 2 scalp reductions and hair transplants in the frontal area that imparted a plug-like look with an unnatural frontal hairline, hair placed in the wrong direction, scarring in the recipient area, and donor circular scarring from punch excision transplants 25 years prior. He subsequently underwent a temporoparietal flap procedure that resulted in linear scars in the hairline, parietal, and frontal scalp, and still had extensive baldness (Figs. 2A, B). Hair transplantation repair was carried out using 2000 beard hairs, as well as 8000 hairs from the abdomen, arms, legs, and thighs.

Six months after surgery, the hairline has been refined and coverage achieved extending from the hairline and crown (Figs. 2C, D). Nearly 80% of the grafts survived.



**FIGURE 2.** Case 2: A, Top view (before transplantation): Severe baldness involving an area corresponding to level 6 on the Hamilton-Norwood scale; scars of flaps and scalp reduction. B, Right oblique view (before transplantation): Global thinning; hairline scar from flap surgery. C, Top view (6 months after repair with beard and body hair): restored crown, mid scalp, and frontal scalp coverage. D, Right oblique view (6 months after repair with beard and body hair): Global coverage with restored hairline and obscuring of hairline scars.



**FIGURE 3.** Case 3: A, Crown (before transplantation): Bald crown with a Hamilton-Norwood level 6 hair loss. B, Top view (before transplantation): Hamilton Norwood 6 loss with an attempt to comb over the baldness. C, Crown (after global restoration of NW 6 area with head, beard, and body transplants): crown coverage with a natural whorl. D, Top view (after global coverage with head, beard, and body transplants): crown, midscalp, frontal, and nonreceding hairline restoration.

### Patient 3

A 35-year-old white male had severe thinning that involved an area corresponding to a 6 on the Norwood-Hamilton scale of hair loss (Figs. 3A, B). He had no history of previous restoration surgeries, and medical treatments, including finasteride and minoxidil, had been unsuccessful. The patient had been counseled by other hair transplant physicians and considered a poor candidate for global restoration because he had insufficient donor hair available from the middle of the back and sides of the head. In the first surgery, about 15,000 grafts derived from the head (3500), beard (6300) as well as the chest, abdomen, legs, and arms (5200) were added to the entire Norwood 6 area and to create a nonreceding hairline. In the second surgery, 5000 grafts derived from the head area (2500), beard (1500), and chest (1000) were added to the crown, hairline, and midscalp to increase density.

A few months after the last surgery, global coverage was achieved with a nonrecessed hairline (Figs. 3C, D). About 80% of the grafts survived.

### DISCUSSION

The use of FUE in nonhead hair to scalp transplantation has been scantily reported in the literature.<sup>5,6</sup> The advantages of nonhead



hair to scalp transplantation are that the surgeon has an expanded donor supply to enable restoration of hirsute individuals with extensive baldness and inadequate hair donor supply. This expanded donor source has additionally opened new possibilities for individuals with a depleted head donor supply resulting from previous scalp surgeries or accidents, such as burns. For some of these individuals, body hair presents a viable option pending the successful implementation of cultured follicles in hair restoration. Second, the surgeon is presented with a wider variety of hair types from which to choose for specific purposes. For example, an eyebrow transplanted with finer nape hair or leg hair would look more natural than an eyebrow consisting of thick head donor hair; finer nape or leg hair would also result in a softer hairline that many would perceive as looking more natural.

However, there are some disadvantages and limitations to using FUE and its application in nonhead hair to scalp transplantation. First, the technique requires a longer operating time and demands a higher level of operator skills. Second, wide variations in hair angulation, especially in body hair and nape area extractions, call for variation in punch direction and patient position, which puts to the test the surgeon's skill and presents ergonomic challenges for both surgeon and patient. Third, using body and beard hair generally yields hair of inferior quality compared with standard head donor hair. This may cause poorer quality results, particularly in regard to blending with remaining head hair, and patients must be made aware that the result will not be equivalent in quality and quantity to the equivalent of a head hair only transplant. Finally, some patients do not have enough terminal hair to qualify for body to head hair transplantation.

Anecdotal observations by this author in these 3 cases and several other patients suggest that the yield from transplanted hair derived from the chest and abdominal area is about 75% to 80% and at least 80% for beard hair. Although Woods and Campbell<sup>6</sup> showed a 4-fold increase in length of chest hair transplanted to the scalp in their patients, observations did not reveal this to be so in these 3 patients, a test patient, as well as several other cases performed by the author. However, beard hair appears to provide comparable

yields to transplanted head hair and compares favorably to head hair in growth length potential.

A scoring system that could consistently predict the suitability of a candidate for body and beard hair to head transplantation would be helpful toward making this method more universally available as a hair transplant tool to many hair restoration surgeons. In addition, some patients (especially those of African descent) may have tightly curled hair and a harder skin tissue that increases transection rate to an unacceptable level.

Finally, in a predominantly body hair transplant (nonhead and nonbeard), the patient should be counseled to expect that the hair would look best if kept short because body hair will not grow as long as head or beard hair at its maximum length.

Although these case reports provide promising results, a large case series will be necessary to demonstrate that the technique can be applied with reproducible results.

In conclusion, hair transplantation from nonhead donor sources can globally restore even severe bald states in patients with inadequate hair donor supply, including individuals who have undergone prior surgeries in the scalp leading to depletion of their traditional donor supply. What is left of the donor area (if any) is usually not adequate to meet the needs in the balding area. In these individuals, using nonhead hair offers new possibilities.

## REFERENCES

1. Hitzig GS, Schwinning JP, Handler SL. Linear grafting using a modified slot method. Introducing the linear punch. *Dermatol Surg.* 1996;22:788–792.
2. Rassman WR, Bernstein RM, McClellan R, et al. Follicular unit extraction: minimally invasive surgery for hair transplantation. *Dermatol Surg.* 2002;28:720–728.
3. Inaba M. *Androgenetic Alopecia*. Tokyo, Japan: Springer-Verlag; 1996.
4. Harris JA. Follicular unit extraction. *Facial Plast Surg.* 2008;24:404–413.
5. Hirai T, Inoue N, Nagamoto K. Potential use of beards for single-follicle micrografts: convenient follicle-harvesting technique using an injection needle. *Ann Plast Surg.* 2001;47:37–40.
6. Woods R, Campbell AW. Chest hair micrografts display extended growth in scalp tissue: a case report. *Br J Plast Surg.* 2004;57:789–791.
7. Bernstein RM, Rassman WR. The logic of follicular unit transplantation. *Dermatol Clin.* 1999;17:277–295, viii; discussion 296.