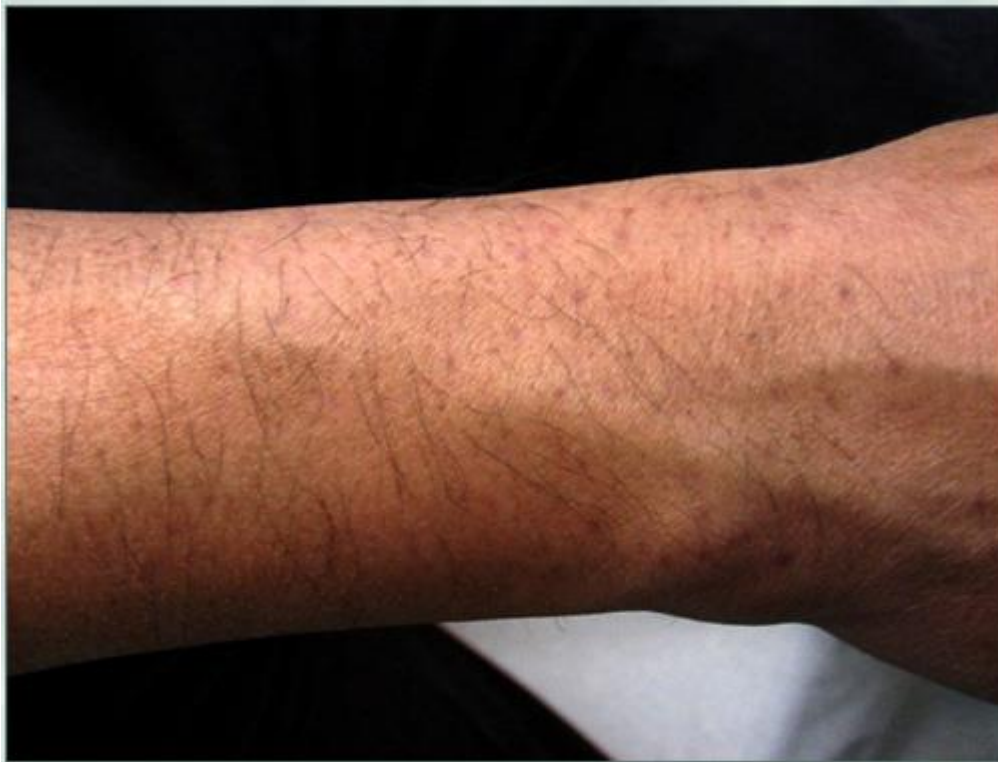

## Wound Healing Sequelae Post Body Transplantation (Variations In Healing Course Following Body Hair Transplantation)

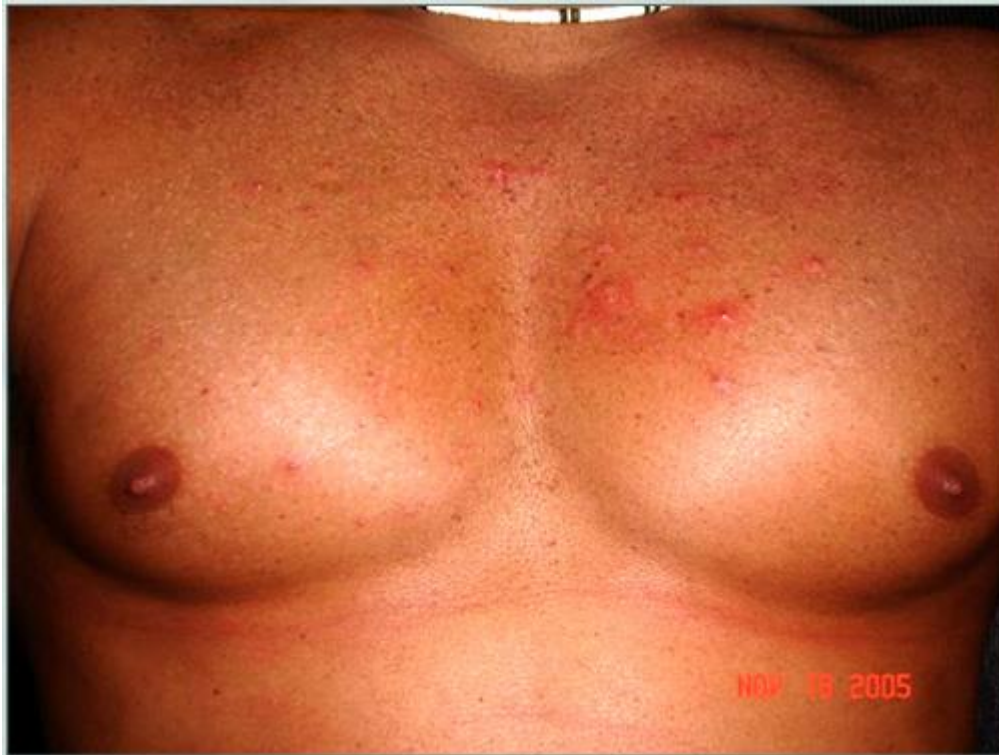Persons with Fitzpatrick type 3-6 skins are prone to healing with initial hyperpigmentation (much like the dark marks that you get temporarily subsequent to an acne attack) Sometimes, instead of dark pigments, you could get lighter/white pigmentation (hypopigmentation) in the initial phase as well. Hypopigmentation can be permanent although it tends to improve over time. However, the causes and histologic pictures of these two situations are similar.

Asiatic (type 4 skin) BHT wound healing with initial Hyperpigmentation:



Heavily tanned caucasian (type 4 skin) BHT chest wounds healing with initial hypopigmentation:

## Wound Healing Sequelae Post Body Transplantation (Variations In Healing Course Following Body Hair Transplantation)

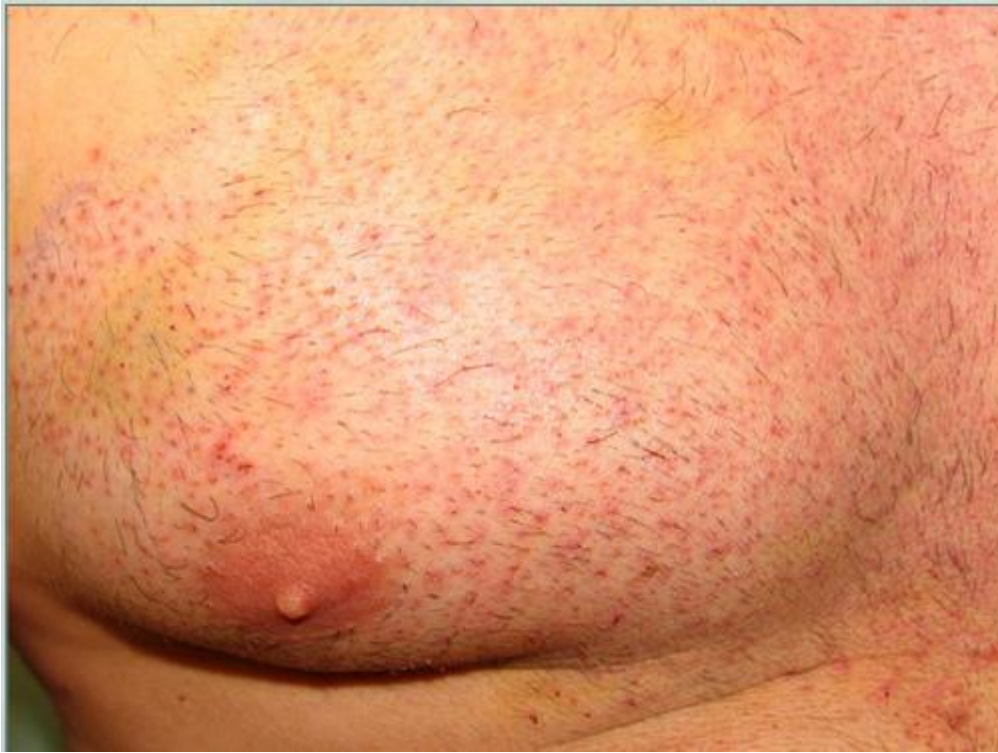


These dyschromias (color changes) tend to improve spontaneously over time, but some hypopigmentation (white dots) may be permanent albeit improved. The improvement of hyperpigmentation (dark spots) can be hastened by the use of fading creams. Wounds that heal initially by hyperpigmentation can end up finally with a much shrunken spot that is either normal in color relative to the surrounding skin or may assume a relatively faintly hyper or hypopigmented hue.

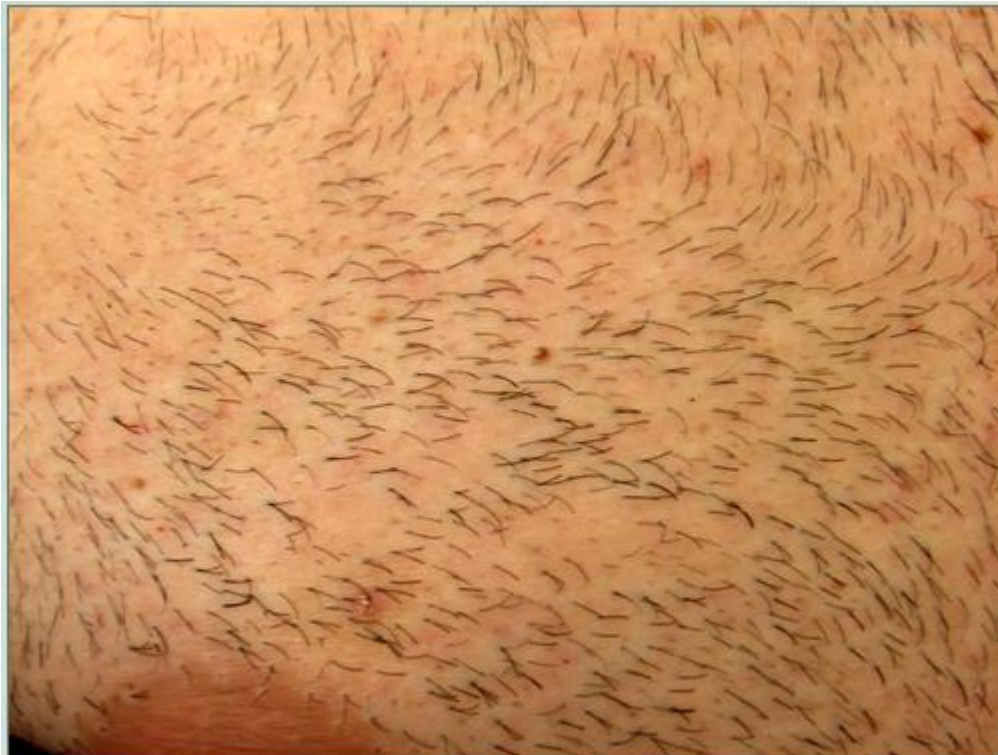**Individuals with type 1-2 skin are less prone to these phenomena:**

Soon after 1700 BHT extractions:

## Wound Healing Sequelae Post Body Transplantation (Variations In Healing Course Following Body Hair Transplantation)



8 weeks later:

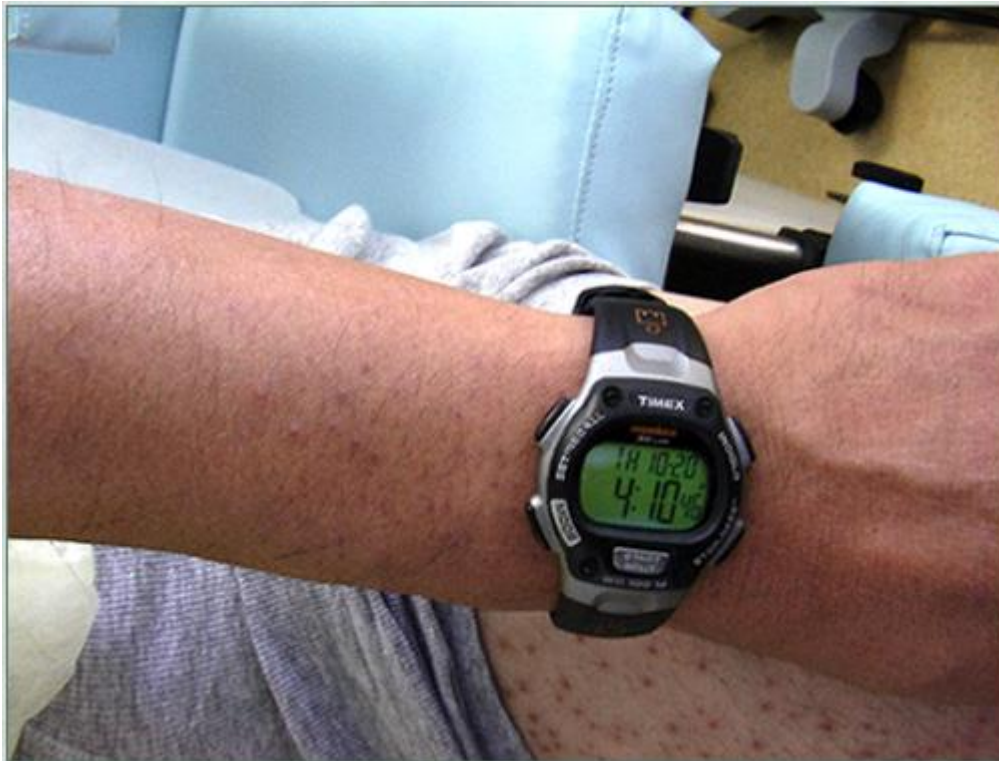

## Wound Healing Sequelae Post Body Transplantation (Variations In Healing Course Following Body Hair Transplantation)

As mentioned earlier, the character of dyschromia (light or dark) can vary from one body region to another even in the same individual regardless of the use of the same wounding technique in both regions. Dark pigmentation post injury is called post inflammatory hyperpigmentation. Thus the extent of the inflammation surrounding the initial wound plays a role in determining the size of the dark spot rather than the size of the wound alone. Factors like the degree of sun exposure, interfering infections etc impacting the region at critical timelines can be influential:

**In the following photos, the patient has had grafts extracted 6 and 12 weeks earlier from both forearm and thigh using the exact same technique:**

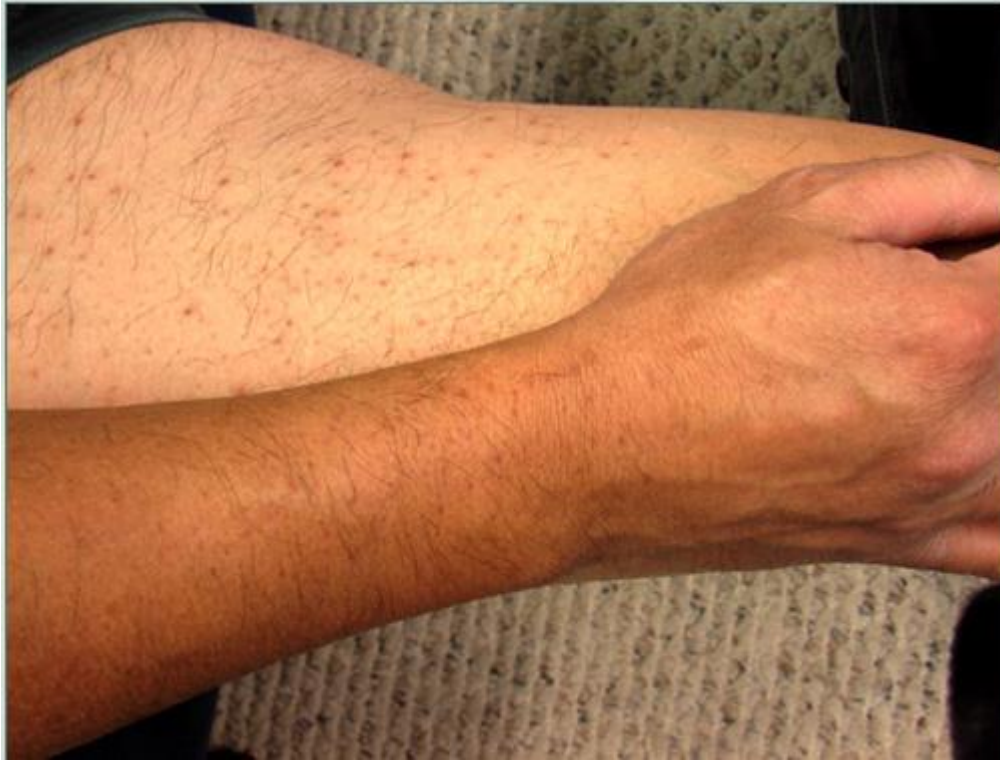At 6 weeks:



At 12 weeks:



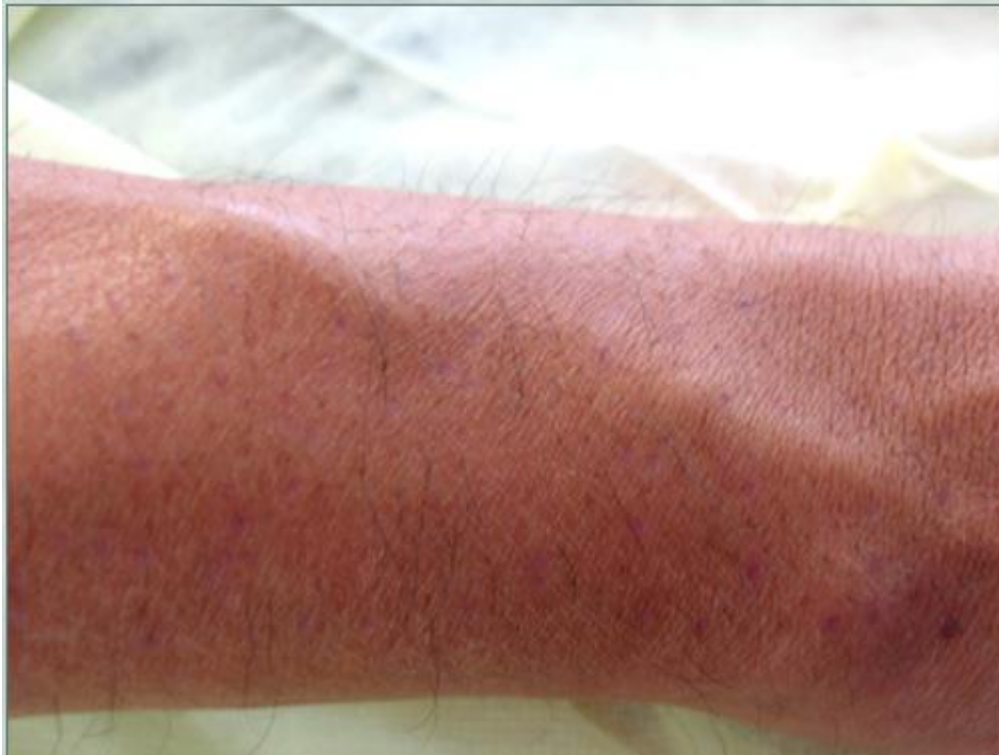## Wound Healing Sequelaes Post Body Transplantation (Variations In Healing Course Following Body Hair Transplantation)



### **Redness post injuries:**

Redness is caused by dilated blood vessels often from the necessary inflammation that accompanies injuries (even small ones). This phenomenon also varies greatly from one individual to another and between techniques. It is more vivid in lighter individuals. In darker persons, redness takes on a violaceous hue which may be missed as it tends to get obscured by the hyperpigmentation:

## Wound Healing Sequelae Post Body Transplantation (Variations In Healing Course Following Body Hair Transplantation)

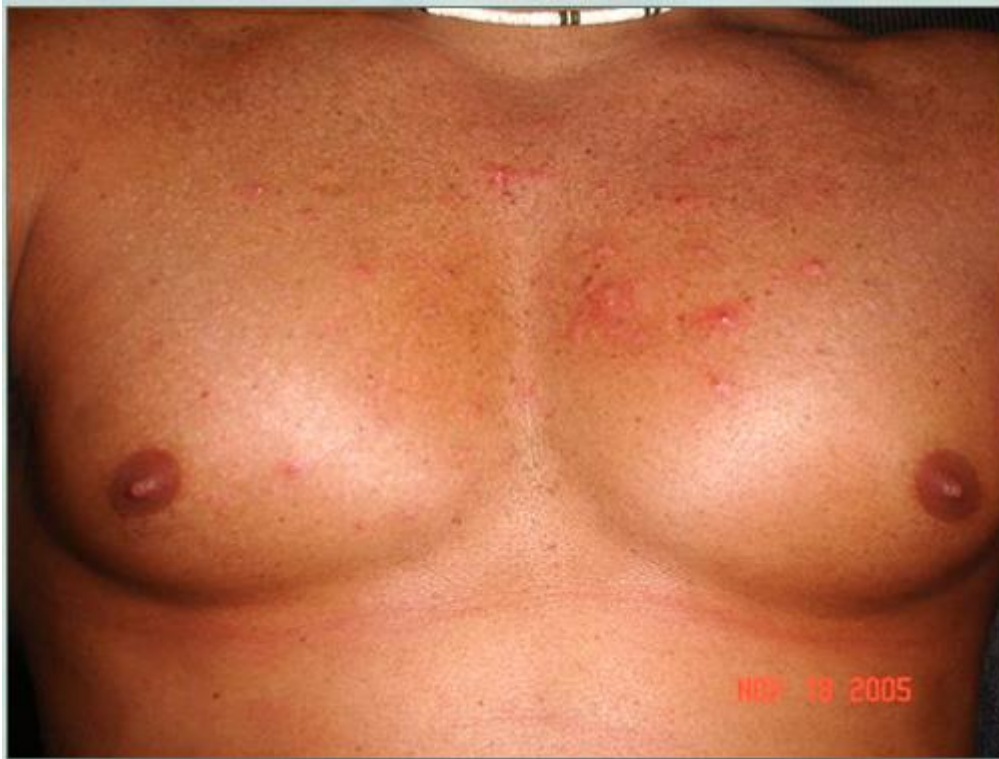

Redness tends to resolve spontaneously over a course of several weeks that could stretch into months in certain individuals. The use of topical steroids could hasten the process.

### **Ingrown hair and BHT timelines**

Ingrown hair and inflammation of the hair follicles could manifest as raised reddish bumps. Typically they tend to resolve within the first 6-8 weeks if they occur at all. Antibiotics and / or steroids may hasten the resolution process but are not always necessary.

## Wound Healing Sequelaes Post Body Transplantation (Variations In Healing Course Following Body Hair Transplantation)



### Scar growth and remodeling

Darker individuals are more prone to scar growth (hypertrophy or even keloids) following any kind of wounding. Non keloidal scar related bumps tend to undergo remodeling leading to spontaneous improvement over time although the process can be hastened by the use of steroid injections, creams, silicone based therapies, massage etc. Keloidal scars would continue to grow beyond the confines of the wound in a tumor-like fashion. When they occur, they are hard to miss. They occur more often in darker individuals with regional variability even in the same individual. They favor areas of high tension and are notoriously attracted certain areas e.g mid upper chest. These would usually require interventions that vary in extent (steroid creams-injections, silicone based treatments, interferons, surgery, pressure, radiation treatment etc). Individuals prone to keloids should avoid unnecessary surgeries and must notify their surgeons before any procedure is performed.

Please direct all enquiries to S. Umar, MD. 819 North Harbor Drive, Suite 400, Redondo Beach, California [drumar@dermhairclinic.com](mailto:drumar@dermhairclinic.com) tel 1-877-DERMHAIR