



# Patient selection criteria and innovative techniques for improving outcome and cosmesis in acne keloidalis nuchae lesion excision and primary closure

Sanusi Umar, MD,<sup>a,b,c</sup> Jason R. Castillo, MD,<sup>c</sup> Consuelo V. David, MD, MSc,<sup>c</sup> and Sophia Sandhu, MD<sup>c</sup>  
Los Angeles, Redondo Beach, and Torrance, California

**Key Words:** acne keloidalis nuchae; narrow scar; posterior hairline; primary closure; secondary intention healing; trichophytic closure; trichophytic excision.

## INTRODUCTION

Acne keloidalis nuchae (AKN) is characterized by clusters of follicular-based papules and pustules that may coalesce to form plaques, which resemble hypertrophic or keloid-like scars on the occipital scalp or posterior neck. Although AKN primarily affects men of color,<sup>1,2</sup> it can rarely occur in women and whites.<sup>3</sup>

Although a variety of treatments are available for AKN, only surgery and laser epilation are curative for severe cases or situations in which conservative treatment has failed.<sup>4-11</sup> The 2 most favored surgical procedures are AKN excision with secondary intention healing (SIH) and AKN excision with primary closure.<sup>5-11</sup> These procedures have yielded mixed results related to recurrence and scarring,<sup>12</sup> which may be due in part to the absence of patient criteria that predict good outcomes. The current report describes 3 patients in whom innovative surgical methods were used for AKN lesions that were  $\leq 3$  cm vertical width, located in the upper half of the nuchal area (Fig 1) and unresponsive to prior nonsurgical treatments. These techniques were intended to extend the AKN excision and primary closure approach for reduced recurrence and improved scar cosmesis. Written informed consent was obtained for all procedures.

### Abbreviations used:

AKN: acne keloidalis nuchae  
SIH: secondary intention healing

## PATIENT 1

An African man, age 49 years, presented with a less than 2.5 cm vertical width AKN lesion in the upper half of the nuchal area (Fig 2). Prior nonsurgical approaches, including topical and injected steroids, were not successful. With the goal of creating a well-camouflaged scar, trichophytic excision and closure were performed following steps A through E illustrated in Fig 3. The process began with an elliptical excision at the level of the galea using an electrosurgical tip capable of cutting and coagulating. The superior wound margin was then incised with the bevel slanted to stay parallel to the hair angles, resulting in an inverted wound edge. Next, trichophytic excision was performed by shaving the skin 2 to 4 mm around the inferior wound edge to decapitate viable hair follicles at the papillary dermal level. Finally, 2-layered trichophytic closure was performed by using deep absorbable 2-0 polyglactin sutures in an interrupted, buried fashion with profound bites taken off the reticular dermis, followed

From the Department of Medicine, Dermatology Division, University of California at Los Angeles<sup>a</sup>; Dr U Hair and Skin Clinic, Redondo Beach<sup>b</sup>; and Dermatology Division, Harbor-UCLA Department of Medicine.<sup>c</sup>

Funding sources: None.

Conflicts of interest: None disclosed.

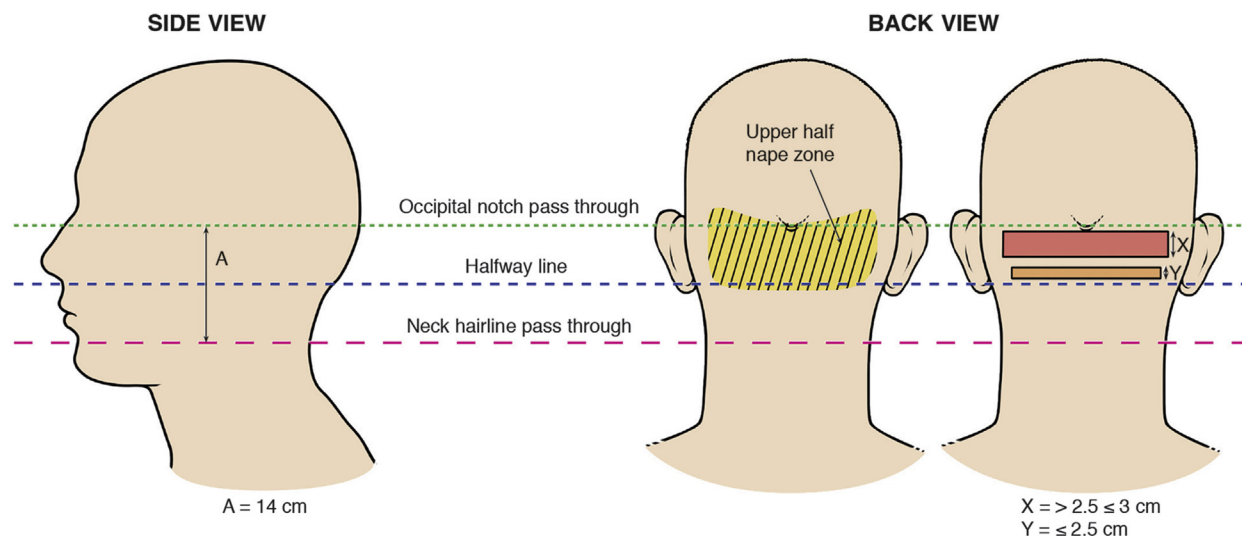
Correspondence to: Sanusi Umar, MD, Dr U Hair and Skin Clinic, 510 N. Prospect Avenue, Suite 209, Redondo Beach, CA 90277. E-mail: [drumar@dru.com](mailto:drumar@dru.com).

JAAD Case Reports 2019;5:24-8.  
2352-5126

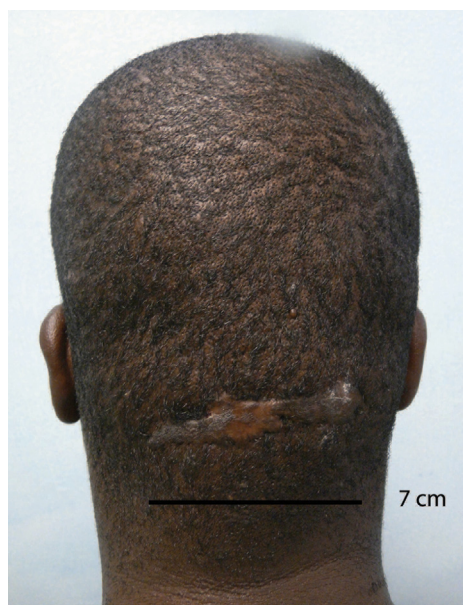© 2018 by the American Academy of Dermatology, Inc. Published by Elsevier, Inc. This is an open access article under the CC BY-NC-ND license (<http://creativecommons.org/licenses/by-nc-nd/4.0/>).

<https://doi.org/10.1016/j.jidcr.2018.10.002>

## Anatomical Landmarks



**Fig 1.** Side and back view of the head show anatomical landmarks and posterior scale.

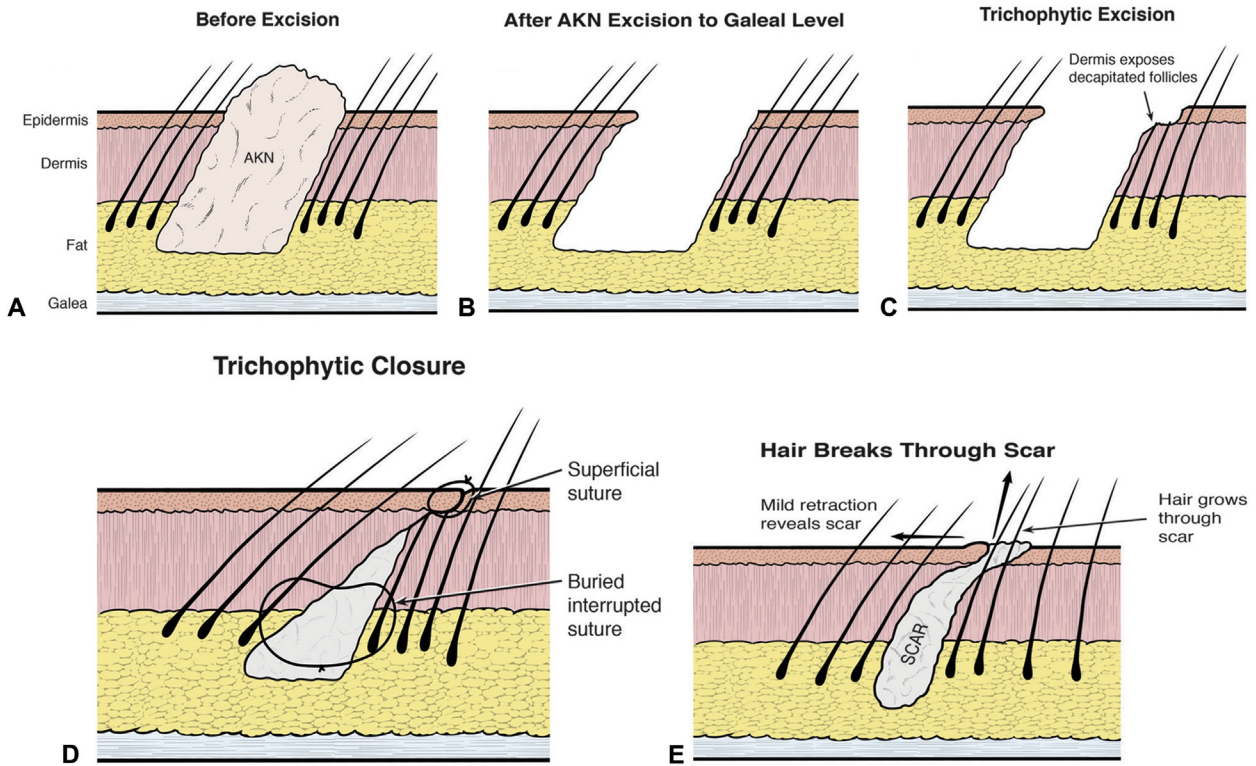


**Fig 2.** Patient 1, an African man, age 49 years, with a lesion of less than 2.5 cm vertical width in the upper half of the nuchal area.

by superficial closure accomplished through bringing the edges of the superior wound margin to appose and cover the exposed zone of trichophytic excision. The wound was covered with a thick layer of bacitracin ointment, and the running sutures were removed 7 days later. At 1 year, the scar was still well camouflaged by hair growth through it (Fig 4). No stretching of the scar was noted, and no AKN recurrence was reported.

### PATIENT 2

An African-American man, age 48 years, presented with a 3-year history of a painful and pruritic draining 4 × 3 × 1-cm nodular firm plaque (vertical width, 3 cm) on the upper half of the nuchal area that developed after shaving his head. Previous treatments with intralesional steroids and oral antibiotics failed to resolve the lesions. As a result, the patient kept his hair long to hide the lesions. For optimal scar camouflage and to minimize the occurrence of a stretched scar from dehiscing forces, trichophytic excision and closure followed by application of tension sutures illustrated in steps A through C in Fig 5 were performed. Previously described elliptical AKN excision and trichophytic excision of the inferior wound margin and a 2-layered trichophytic closure were performed. Tension sutures were deployed using size 0 polydioxanone in an interrupted horizontal mattress fashion between the inferior and posterior margins of the wound in 2 positions (the middle of the left and right halves of the wound's horizontal length). The horizontal mattress sutures were exteriorized in pairs 1 to 2 cm away from the superior and inferior wound, but not knotted to permit suturing work on the wound. Povidone-iodine-soaked 4 × 4 gauze pads were folded into quarters underneath the cutaneous entry and exit points of the sutures on either side of the wound margins to minimize direct suture tension on the skin, ischemia, and suture cut-through of the skin (Fig 6). Sutures were then tied with sufficient tension to bring about a visible puffing of the scalp in



**Fig 3.** Steps A-E show the methodology of elliptic AKN excision, trichophytic excision of inferior wound margin, trichophytic closure, and postsurgery.



**Fig 4.** Patient 1 one year after AKN excision with trichophytic closure. The scar is still thin and well camouflaged.

between tension sutures. The wound was covered with a thick layer of bacitracin ointment followed by Telfa, 4 × 4 gauze and Kerlex bandages. There were no complications intraoperatively. The patient continued on mupirocin 2% ointment and advised to soak the bolster sutures daily with betadine solution. Skin (area) sutures were removed day 7 after surgery, and tension sutures removed approximately 4 weeks after the elliptical excision, at which time they were noted to have lost their tautness.

Four months postoperatively, the patient had no evidence of AKN recurrence and comfortably sported a uniformly short haircut (Fig 7). At

14 months' follow-up, the scar remained thin and well camouflaged.

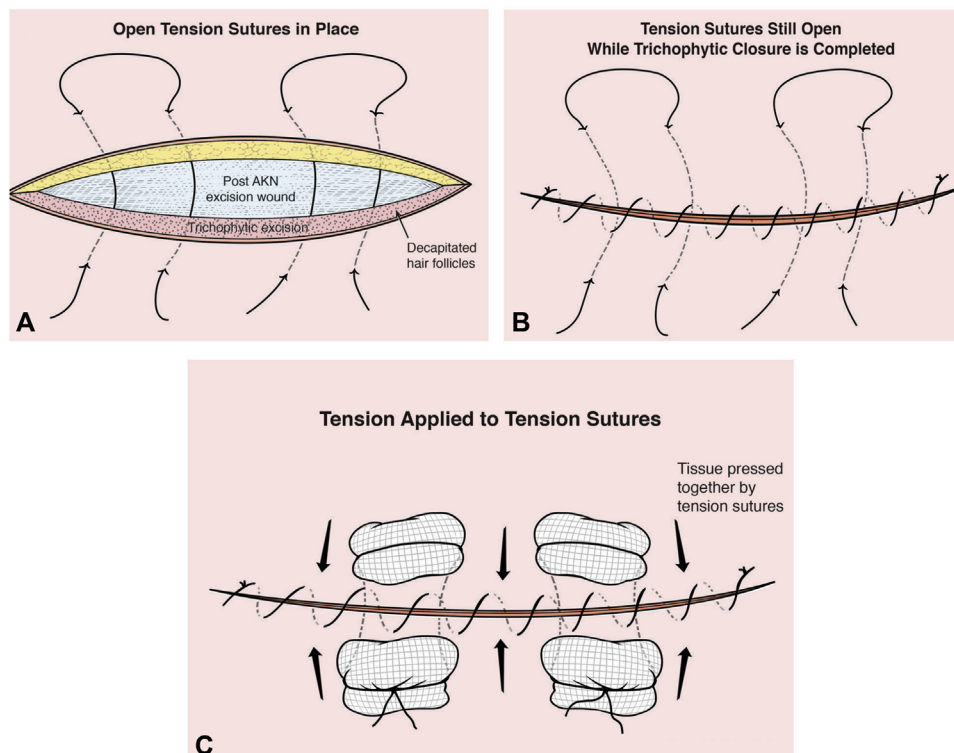
**PATIENT 3**

An African-American man, age 46 years, presented with a diagonally disposed linear 6.5- × 3- × 0.5-cm plaque on the upper part of the nuchal area that was painful and occasionally discharged blood and pus. The lesion had been recalcitrant to steroid injections and ointments as well as oral antibiotics. The procedure described in patient 2 was performed. Tension sutures significantly lost their tautness at 2 weeks and were removed along with superficial wound sutures. Results on follow-up showed a well-camouflaged and stable scar with minimal stretch.

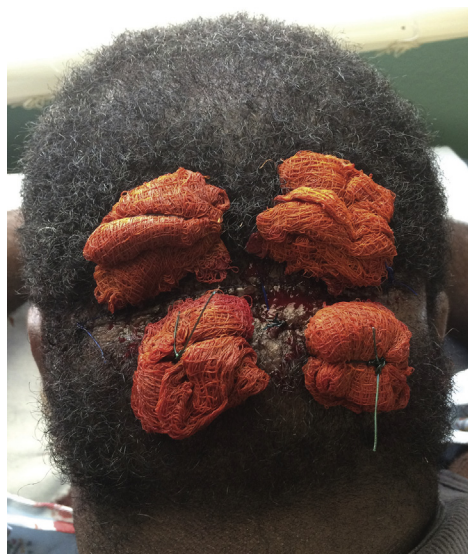**DISCUSSION**

To minimize the frequently reported problems of unsatisfactory outcomes of recurrence and scarring after surgical removal of AKN lesions,<sup>9,12</sup> the lead author used criteria for selecting patients undergoing excisions with primary closure (compared with excisions with SIH). Excision followed by SIH is a preferred approach for (1) lesions with vertical width of >3 cm that are completely located between the boundary defined by the occipital notch superiorly and the posterior hairline, and (2) lesions with



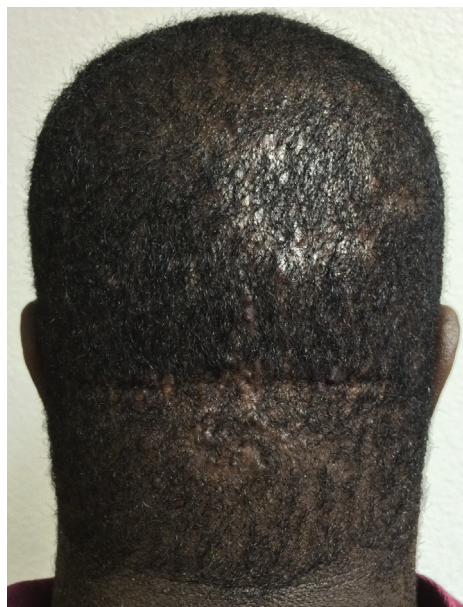

**Fig 5.** Steps A-C show the methodology of insertion of deep interrupted sutures and trichophytic closure after elliptical AKN excision and trichophytic excision of inferior wound margin.



**Fig 6.** Patient 2 after application of tension sutures that are padded with povidone-iodine-soaked gauze pads.

vertical height of  $\leq 3$  cm located in the lower half of the nape area (Fig 1). For both types of lesions, tension sutures are used to aid SIH if the vertical height is greater than 3 cm or if the lesion spread breaches the defined boundary (Umar et al, unpublished data).



**Fig 7.** Patient 2 at 4 months. The scar is thin, with hair growing through to camouflage it. Residual AKN was treated with clobetasol solution.

In contrast, the results of this case series, although limited in number, suggest that patients with lesions  $\leq 3$  cm and disposed in the upper half of the nuchal

area are good candidates for excision with primary closure. Lesions fitting this latter criterion are not ideal for excision and SIH because they are too distant from the posterior hairline and too much normal scalp would have to be sacrificed to include the posterior hairline in the excision.

Anecdotal experience and reports by other researchers initially suggested that good results can be achieved by primary closure for scalp lesions of 2.5 cm or less.<sup>13</sup> However, this can be extended up to approximately 3 cm by adding the use of tension sutures. There would likely be variations depending on a patient's scalp laxity and glidability, but for standardization and the likelihood of obtaining more consistent results, a cutoff of 3 cm achieves the best balance.

In addition, if the posterior hairline is not included in AKN excision, the scar formed would be above the posterior hairline instead of becoming the new posterior hairline if the posterior hairline was included in the excision. Horizontal scars that define the posterior hairline area camouflage better than scars that exist above the posterior hairline.<sup>7</sup> Lesions meeting this criterion of  $\leq 3$  cm vertical height and disposed in the upper half of the nuchal area are ideal for primary closure because they are located closer to the occipital protuberance (the fulcrum) and less susceptible to the magnitude of contraction and stretching when the neck is flexed and extended. The result is less stretching of a scar that would occur compared with lesions disposed in mid or lower portions of the nuchal area. This concept is supported by Seery<sup>14</sup> although he ascribed the difference in terms of number of tissue layers (5 vs 3) and its influence on scalp glidability. However, there are likely to be several contributing factors, including mechanical forces; for example, in lesions  $\leq 3$  cm vertical width, the excision wound is subjected to less dehiscing forces compared with larger width lesions.

After AKN excision and primary closure, the scar that forms is a hairless zone that attracts attention. This result is further compounded by any increase in scar width that can occur if the scar stretches.<sup>6,10</sup> Trichophytic excision and closure, which results in hair growing through the scar, anticipates and reduces this concern to result in a well-camouflaged scar that is less detectable. None of the patients required scar revision.

According to Gloster,<sup>6</sup> patients need to maintain an upward-facing neck posture to reduce the stretching forces in the wound after excision with primary closure. By applying tension sutures for a duration of 4 weeks or until they significantly lose their tautness, the need to keep the head up is minimized. When the combination of trichophytic closure and vertical

width limits is considered in patient selection criteria, the chance of a better-camouflaged, thinner scar is enhanced. Adding tension suturing to lesions of width between 2.5 and 3.0 cm further complements the process and minimizes the imposition of strictly maintaining an uncomfortable neck posture. Finally, the creation of tension around the wound (by way of tension sutures) favors contraction of the wound that translates into thinner scars. Manipulation of tension on the wound inside the first 48 hours of wounding influences fibroblasts to ultimately become differentiated myofibroblasts which are pivotal to the contractile ability of the wound,<sup>15</sup> increasing resistance in the tissue surrounding wounds also induces differentiation of myofibroblasts to initiate and enhance wound contraction.<sup>16</sup>

#### REFERENCES

1. Alexis A, Heath CR, Halder RM. Folliculitis keloidalis nuchae and pseudofolliculitis barbae: are prevention and effective treatment within reach? *Dermatol Clin* 2014;32:183-191.
2. Kelly AP. Pseudofolliculitis barbae and acne keloidalis nuchae. *Dermatol Clin*. 2003;21:645-653.
3. Azurdia RM, Graham RM, Weismann K, Guerin DM, Parslew R. Acne keloidalis in Caucasian patients on cyclosporin following organ transplantation. *Br J Dermatol*. 2000;143:465.
4. Esmat SM, Abdel Hay RM, Abu Zeid OM, Hosni HN. The efficacy of laser assisted hair removal in the treatment of acne keloidalis nuchae; a pilot study. *Eur J Dermatol*. 2012;5:645-650.
5. Cosman B, Wolff M. Acne keloidalis. *Plast Reconstr Surg*. 1972; 50:25-30.
6. Gloster HM. The surgical management of extensive cases of acne keloidalis nuchae. *Arch Dermatol*. 2000;136:1376-1379.
7. Glenn MJ, Bennett RG, Kelly AP. Acne keloidalis nuchae: treatment with excision and second-intention healing. *J Am Acad Dermatol*. 1995;33:243-246.
8. Bennett RG. Acne keloidalis. In: Bennett RG, ed. *Fundamentals of Cutaneous Surgery*. St Louis: CV Mosby; 1988:759-762.
9. Califano J, Miller S, Frodel J. Treatment of occipital acne keloidalis by excision followed by secondary intention healing. *Arch Facial Plast Surg*. 1999;1:308-311.
10. Bajaj V, Langtry JA. Surgical excision of acne keloidalis nuchae with secondary intention healing. *Clin Exp Dermatol*. 2008;33: 53-55.
11. Beckett N, Lawson C, Cohen G. Electrosurgical excision of acne keloidalis nuchae with secondary intention healing. *J Clin Aesthet Dermatol*. 2011;4:36-39.
12. Maranda EL, Simmons BJ, Nguyen AH, Lin VM, Keri JE. Treatment of Acne keloidalis nuchae: A systematic review of the literature. *Dermatol Ther (Heidelb)*. 2016;6:363-378.
13. Umman P, Pillai VG, Abraham PM, Varkey RG. Rotation flap closure of moderate size scalp defects — technique and outcome. *J Clin Diag Res*. 2016;10:PD21-PD23.
14. Seery GE. Surgical anatomy of the scalp. *Dermatol Surg*. 2002; 28:581-587.
15. Tomasek JJ, Gabbiani G, Hinz B, Chaponnier C, Brown RA. Myofibroblasts and mechano-regulation of connective tissue remodeling. *Nat Rev Mol Cell Biol*. 2002;3:349-363.
16. Hinz B, Mastrangelo D, Iselin CE, Chaponnier C, Gabbiani G. Mechanical tension controls granulation tissue contractile activity and myofibroblast differentiation. *Am J Pathol*. 2001; 159:1009-1020.